

COMPLICATIONS OF OLD FRACTURES OF THE NECK OF THE FEMUR RESULTS OF TREATMENT BY VITALLIUM-MOLD ARTHROPLASTY*

BY M. N. SMITH-PETERSEN, M.D., CARROLL B. LARSON, M.D., AND OTTO E. AUFRANC, M.D.,
BOSTON, MASSACHUSETTS, AND W. ALEXANDER LAW, F.R.C.S., LONDON, ENGLAND†

INTRODUCTION

Vitallium-mold arthroplasty has been performed in forty-two cases, presenting complications of femoral-neck fractures, during the past seven and one-half years. This is a small series, and some of the cases reported fall into the class of "early" rather than "end" results. Our statistics, therefore, may change for better or for worse, as the years go by. It is fair to say that the study of results up to the present time is encouraging.

OPERATIVE PROCEDURES

Mold arthroplasty consists in first creating a joint as nearly perfect, mechanically, as possible, and then guiding nature's repair by means of an inert mold, and carefully supervised exercises. As applied to the treatment of complications of fractures of the femoral neck, the procedure is varied, according to the extent of the degenerative changes; four different types of mold arthroplasty have resulted:

1. Routine mold arthroplasty;
2. Modified Whitman reconstruction operation;
3. Modified Colonna reconstruction operation;
4. Intertrochanteric mold arthroplasty.

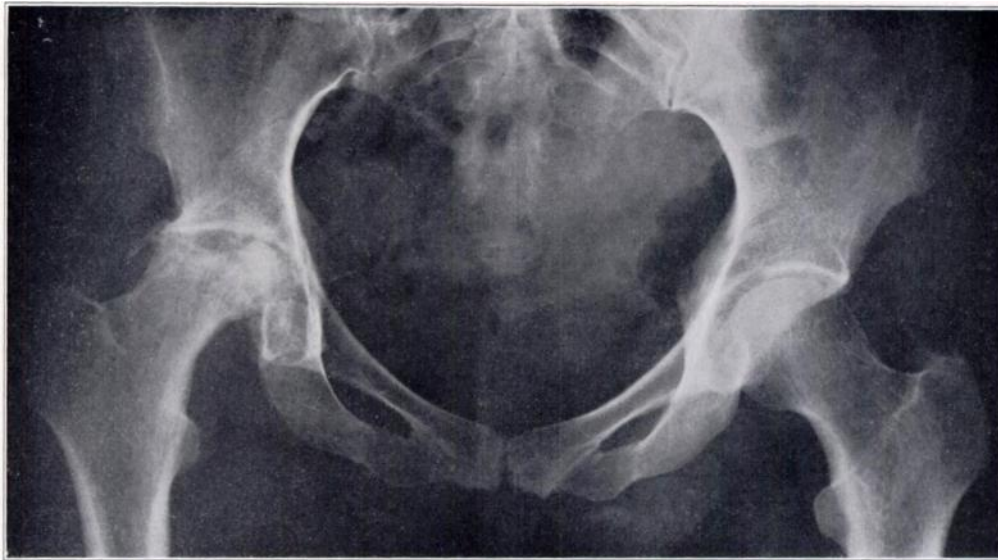


FIG. 1-A

Case A. F. Moderate aseptic necrosis of the femoral head in a woman, forty-eight years old. She had sustained a subcapital fracture two years previously and had been treated by traction for five weeks, followed by partial weight-bearing on crutches for six months. Full weight-bearing without pain was possible until sixteen months after the accident; at this time onset of pain necessitated return to crutches. Vitallium-mold arthroplasty was performed two years and three months after injury. This was a very favorable case, because the aseptic necrosis was moderate; bone and muscle atrophy was also moderate, due to the absence of complete immobilization and to persistent, even though limited, function.

* Presented at the Annual Meeting of The American Orthopaedic Association, Hot Springs, Virginia, June 29, 1946.

† On Rockefeller Travelling Fellowship.

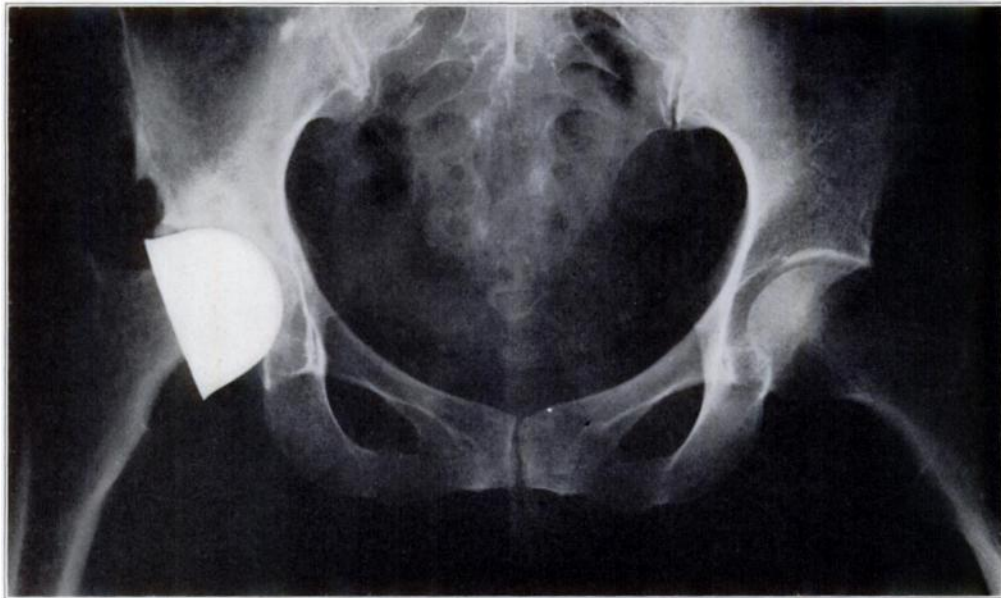


FIG. 1-B

Two and one-half years after the arthroplasty, the report of the examination read: "Walks without a limp, no pain. One-half inch of shortening. Motions: Hyperextension, 5 degrees; flexion, 115 degrees; internal rotation, 10 to 15 degrees; external rotation, 15 to 20 degrees; abduction, 20 degrees; adduction, 20 degrees." Patient returned to her work as a music teacher in the public schools ten months after the arthroplasty.

This case illustrates the result of a routine mold arthroplasty for limited aseptic necrosis of the femoral head.

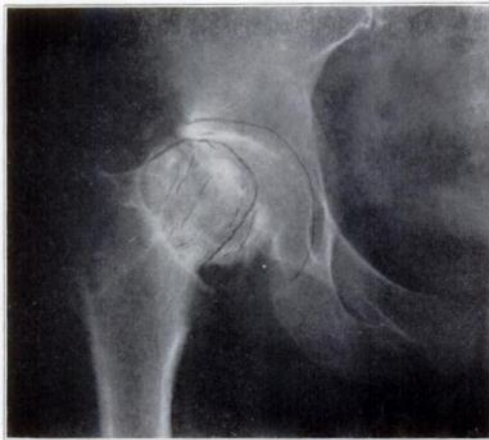

FIG. 2-A

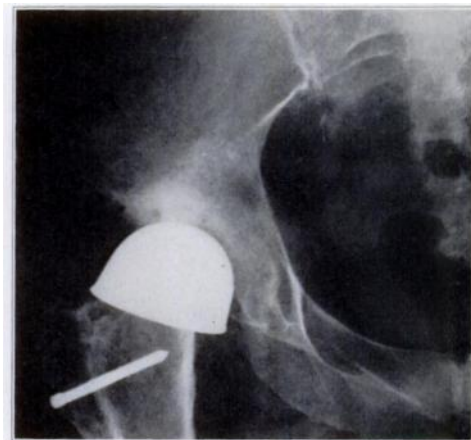


FIG. 2-B

Fig. 2-A: A.T. Extensive aseptic necrosis of femoral head and proximal neck in a woman, fifty-seven years old. She had sustained a fracture of the distal neck four and one-half years previously and had been treated by nailing. (This roentgenogram is instructive, because it illustrates the surgeon's habit of outlining the contemplated operative procedure.) In this case the acetabulum was not deepened as planned, because, after removal of the area of necrosis, the neck was found to be too short. Grafts from the iliac crest were introduced into the distal neck and the vitallium mold was applied. The greater trochanter was not transplanted; this was an error in judgment on the part of the surgeon. Six months later the trochanter had to be transplanted, because the reconstructed neck had rotated out of the mold.

Fig. 2-B: Roentgenogram taken eighteen months after arthroplasty, twelve months after transplantation of the greater trochanter. Motions possible at this time: extension, complete; flexion, 90 degrees; abduction, 15 degrees; internal rotation, 15 degrees; external rotation, 10 degrees. There was shortening of five-eighths of an inch. The patient is leading a fairly normal life; swimming and horseback-riding are included in her activities. She uses a cane for outdoor walking.

This case illustrates the result of a modified Whitman arthroplasty for extensive necrosis of the femoral head and proximal neck.

1. Routine Mold Arthroplasty

In aseptic necrosis of the head, limited in extent and occurring after union of the fractured neck, a routine mold arthroplasty is indicated. This consists in reshaping the head and acetabulum so as to create two congruous surfaces; the "crater" representing the necrotic area is excised down to bleeding bone and, in cases of relatively extensive necrosis, the resulting defect is packed with cancellous bone from the iliac crest. The reshaped femoral head is covered with a vitallium mold and replaced in the acetabulum (Figs. 1-A and 1-B).

2. Modified Whitman Reconstruction Operation

When the aseptic necrosis involves most of the head, even though the fracture has united, a modified Whitman reconstruction is indicated. This consists in discarding the "dead head", reshaping

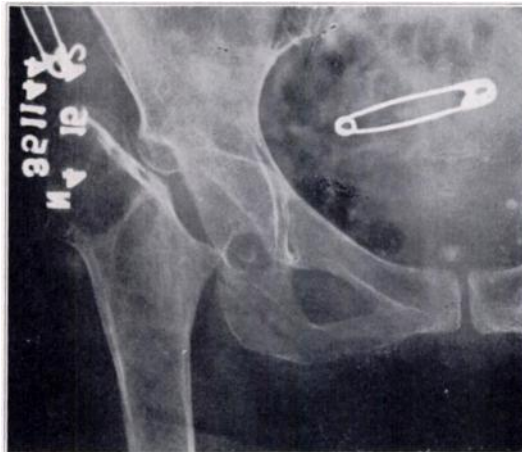


FIG. 3-A

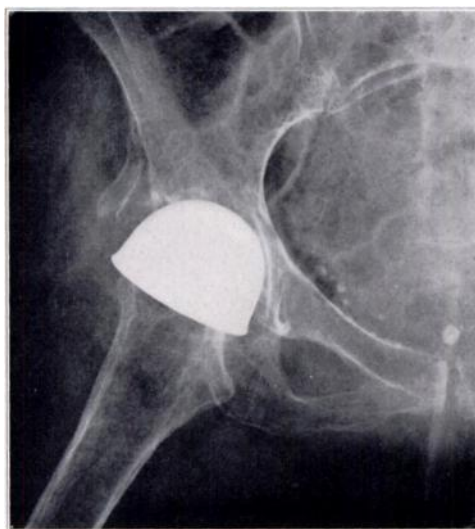


FIG. 3-B

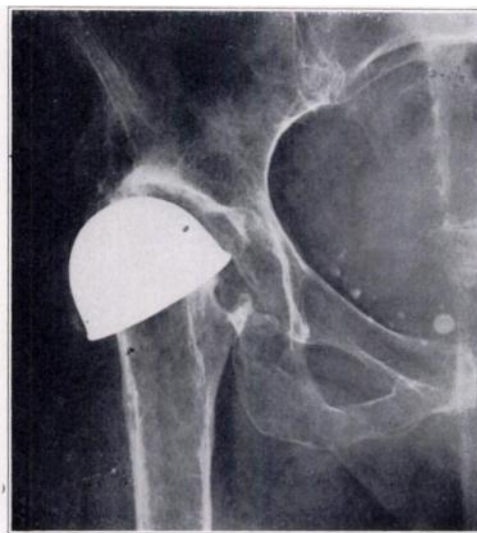

FIG. 3-C

Fig. 3-A: H. P. Complete absorption of right femoral head and neck with marked atrophy of pelvis and shaft of femur in a woman, fifty-eight years old. She had sustained a fracture of the distal neck four and one-half years previously and had been treated by internal fixation by means of two pins. Non-union had become evident six months later and the pins had been removed. Roentgenogram illustrates a local condition most unfavorable for arthrodesis or osteotomy.

Fig. 3-B: One month after a "modified Colonna". The acetabulum has been deepened medially and posteriorly and its anterior wall excised. The anterior third of the ilium has been osteotomized vertically, and its outer cortex displaced laterally; bone grafts from the iliac crest have been packed into the osteotomy gap. In the abducted position, the trochanter, covered by the mold, is in apposition to the floor of the acetabulum. The superior aspect of the lesser trochanter has been excised to prevent impingement against the inferior acetabulum.

Fig. 3-C: Four years after mold arthroplasty. With the hip in neutral, as far as abduction and adduction are concerned, the trochanter rests against the lateral acetabulum; the osteotomy of the ilium has extended the superior acetabular border, thereby preventing subluxation of the femoral head. There is a wide joint line, indicative of a cartilaginous lining of the acetabulum. Motions possible at this time: extension, complete; flexion, 110 degrees; abduction, 25 degrees; adduction, 30 degrees; internal rotation, 25 degrees; external rotation, 25 degrees. There was shortening of two inches. This patient does all her household duties; climbs stairs normally; uses a cane only for outdoor walking; does not complain of pain.

the viable remaining neck, covering it with a vitallium mold, and replacing it in the acetabulum. In the majority of cases, it has been our experience that the viable neck is too short and that osteotomy of the greater trochanter and transplantation to the subtrochanteric region are indicated. This is, therefore, a typical Whitman reconstruction procedure, with the addition of the vitallium-mold arthroplasty (Figs. 2-A and 2-B).

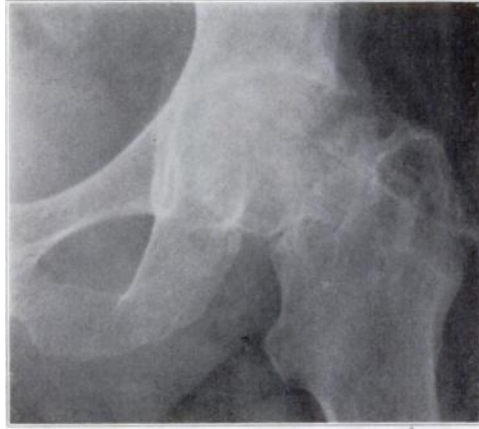

FIG. 4-A

3. *Modified Colonna Reconstruction Operation*

In non-union with a dead head and more or less complete absorption of the neck, a "modified Colonna" operation is indicated. This consists in creating a deep acetabulum and freeing all muscle attachments from the greater trochanter down to the infratrochanteric region. After the trochanter has been shaped with reamers, care being taken to sacrifice a minimum amount of bone, the mold is applied and the greater trochanter is intro-

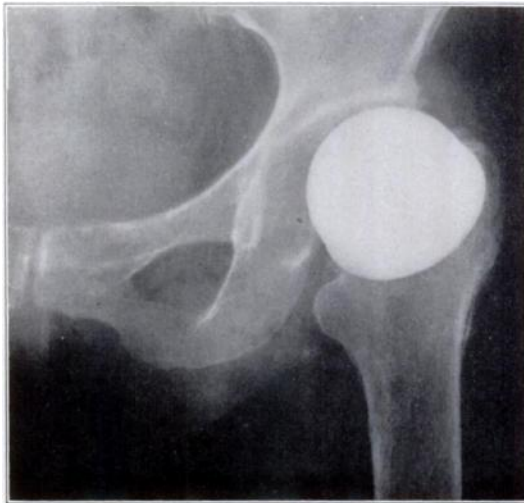


FIG. 4-B

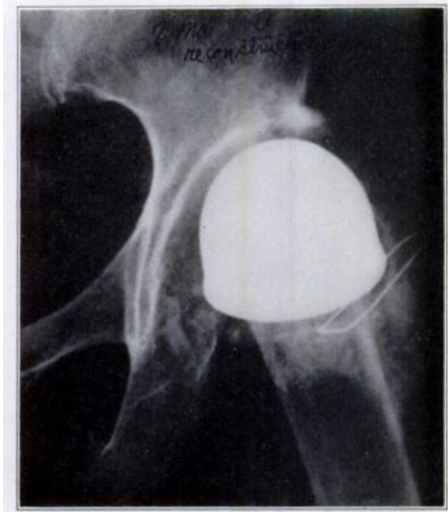


FIG. 4-C

Fig. 4-A: B. G. Aseptic necrosis of femoral head and proximal neck in a woman, forty-nine years old. She had sustained a mid-neck fracture twenty-two months previously, and had been treated by plaster cast for seventeen weeks. Eleven months after the fracture, "nailing" had been done. Fibrous union with extensive aseptic necrosis had resulted.

Fig. 4-B: Eight months after the mold arthroplasty. There was an error of judgment on the part of the surgeon in this case; the greater trochanter should have been osteotomized and transplanted downward, in order to create a better mechanical joint. Aseptic necrosis had progressed inside the mold, until the mold came to rest on the greater and lesser trochanters, producing pressure changes accompanied by pain.

Fig. 4-C: Roentgenogram taken seven months after revision of the arthroplasty. At the time of this operation, the greater trochanter presented such extensive changes that a modified Colonna was considered inadvisable. The lesser trochanter was excised subperiosteally, and the intertrochanteric region was reshaped to fit the mold. The atrophied greater trochanter, with its muscle attachments, was transplanted to the infratrochanteric region. Examination at this time showed mobility as follows: extension, complete; flexion, 95 degrees; abduction, 50 degrees; adduction, 5 degrees; internal rotation, 20 degrees; external rotation, 20 degrees. There was shortening of two inches. The patient does not complain of pain, but has a marked short-leg limp.

This case illustrates the importance of creating a joint mechanically able to transmit weight, even if this requires transplantation of the greater trochanter.

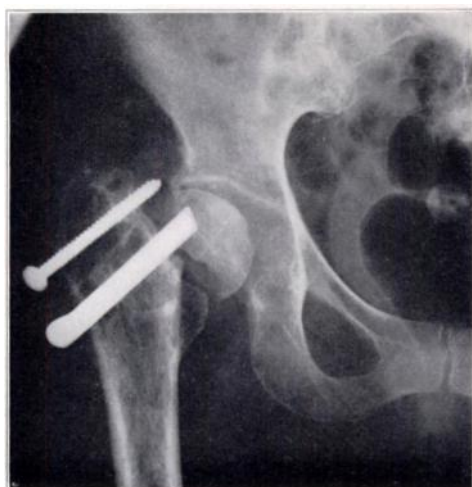

FIG. 5-A

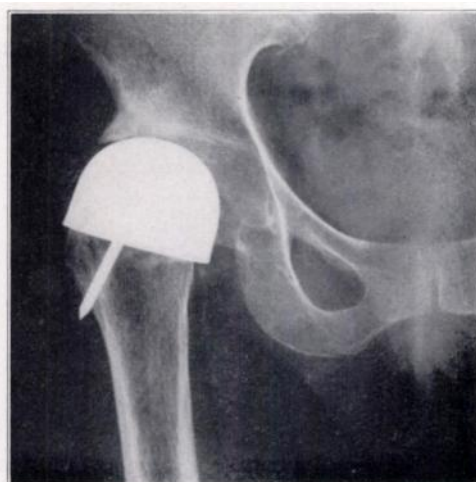

FIG. 5-B

Fig. 5-A: A. M., a woman, fifty-six years old. Showing a "dead head", absorption of the neck, and advanced atrophy of the greater trochanter. There is also evidence of bone absorption around the nail and the screw. In this case, also, the local condition is unfavorable for osteotomy or arthrodesis.

Fig. 5-B: Roentgenogram taken twenty-seven months after a modified Colonna with osteotomy of the greater trochanter, as described in the text. Report of examination: Walks without a cane with some limp; no limp when walking with a cane. Extension, complete; flexion, 115 degrees; abduction, 25 degrees; adduction, 15 degrees; internal rotation, 35 degrees; external rotation, 35 degrees. Patient does not complain of pain. She returned to her work as a nurse, one year after the arthroplasty.

duced into the acetabulum. The divided muscles are transplanted to the infratrochanteric region and fastened by heavy silk sutures or by wire.

Since the greater trochanter inclines laterally from the axis of the femoral shaft, it has a tendency to be displaced outward from the acetabulum when the extremity is brought into a position of adduction. To prevent subluxation, the anterior inferior ilium is osteotomized vertically, and its outer cortex is sprung laterally; bone grafts from the iliac crest are introduced into the cleft, maintaining the outer cortex in its lateral displacement. By this procedure the acetabulum is deepened by half an inch or so. The lesser trochanter sometimes comes into dangerous proximity to the anterior lip of the cotyloid notch, particularly with the extremity in adduction. Subperiosteal excision of the lesser trochanter, with the distal expansion of the iliopsoas attachment left intact, prevents such mechanical impingement.

4. Intertrochanteric Mold Arthroplasty

In one patient, extensive degenerative changes occurred under the mold, allowing the mold to settle down and come to rest on both trochanters. The greater trochanter became so atrophied that it could not be shaped and used for a "modified Colonna". After subperiosteal excision of the lesser trochanter, the intertrochanteric region was reconstructed to fit the mold, and the atrophied greater trochanter was transplanted to the infratrochanteric region of the shaft. The result looks good on paper, as far as mobility is concerned, but the shortening is deplorable (Figs. 4-A, 4-B, and 4-C).

In another case the greater trochanter was similarly affected, but for a different reason. This time the changes were due to extravagant use of the means of internal fixation,—namely, a three-flanged nail accompanied by a screw. In this case the initial arthroplasty was successful and, in the opinion of the authors, it is a better procedure than that just described. The screw had already performed a partial osteotomy, and it was simple to make the osteotomy complete after removal of the screw. The osteotomy performed was similar to a green-stick fracture. The remnant of the atrophied greater trochanter was

then folded downward and medially, and transfixed in this position by means of a small three-flanged nail. As has already been pointed out, the greater trochanter deviates laterally from the axis of the femoral shaft; this procedure, then, has a favorable effect on the trochanter, as regards its stability in the acetabulum (Figs. 5-A and 5-B).

EVALUATION OF THE RESULTS OF THESE OPERATIVE PROCEDURES
BASED ON PERSONAL EXAMINATIONS AND INTERVIEWS

BY MR. W. ALEXANDER LAW, OF THE LONDON HOSPITAL, LONDON, ENGLAND

The postoperative results in this series of forty-two cases have been assessed by clinical and roentgenographic examinations, and an effort has been made to determine the value of the operation both to the patient and to the surgeon.

Pain in the hip region is minimal in the majority of the cases, and in both early and late postoperative phases. It is usually present in the form of stiffness on rising from a low chair or at the commencement of activity. Patients do not complain of low-back symptoms, nor of stiff knees.

Motion

Mobility of the hip joint has to be considered in conjunction with stability. The greater range of rotation and abduction seen in cases treated by the "modified Colonna" procedure is associated with diminished muscle leverage.

The range of motion achieved by the four operative procedures is shown in Table I.

This motion is invariably smooth and painless, and in no case is there any suggestion of telescoping. It is to be noted that the great majority of these patients have a sufficiently extensive range of hip-joint motion to enable them to dress themselves, including putting on their own shoes and stockings, to sit in comfort in low chairs for protracted periods, and to perform their ordinary household and social activities.

Gait is dependent upon the smooth motion in the hip joint, the stability of the mold in the deepened acetabulum, and muscle power. Strict training and re-education with particular attention to heel-toe movement is most important; and, even in the presence of limb shortening, it is advisable not to raise the heel on the side of the arthroplasty, so that the patient will stretch out the hip and avoid an adductor gait in the early stages. Later, when a good joint is becoming apparent, compensation for shortening is allowable and helps to overcome any Trendelenburg appearance. Unless the gluteal muscles are very weak and the patient is without the support of a cane, a Trendelenburg gait is rarely obvious in these patients, even when climbing stairs.

Residual deformity is more likely to occur, if the operation is complicated by sepsis or failure to maintain the relationship between the mold and the acetabulum. In the majority of the cases, muscle training and exercises prevent any persistent joint deformity, and some degree of shortening alone is present. This is minimal in the patients treated by the routine mold arthroplasty and is more marked after the Colonna and intertrochanteric arthroplasty procedures.

Evaluation of Treatment

The value of this operative treatment to the patient is obvious. Without exception, the younger patients have returned to their work, including such occupations as mining engineer, department-store manager, stenographer, and nurse. The more elderly have been able to perform their social activities, and use a cane for distance walking.

In Table II the functional value of the hip joint, from the point of view of both the patient and the surgeon, is presented; it is to be noted that in two cases the hip is satisfactory to the patient, but not to the surgeon. In three cases, the result is unsatisfactory